Correction of Femoral Valgus Deformity

Ronald van Heerwaarden, MD, PhD[1] Justus-Martijn Brinkman, MD, PhD[1] Yvette Pronk, MSc[2]

[1] Centre for Deformity Correction and Joint Preserving Surgery, Kliniek ViaSana, Mill, The Netherlands
[2] Research Department, Kliniek ViaSana, Mill, The Netherlands

J Knee Surg

Address for correspondence Ronald J. van Heerwaarden, MD, PhD, Centre for Deformity Correction and Joint Preserving Surgery, Kliniek ViaSana, Hoogveldseweg 1, 5451 AA, Mill, The Netherlands (e-mail: r.vanheerwaarden@viasana.nl).

Abstract

In the past two decades, the insights in the causes and development of valgus leg deformities as well as the options for treatment with corrective osteotomies have dramatically changed. New definitions for deformity analysis and planning for corrections have better defined the patients suitable for femoral valgus deformity corrections. Biomechanical research on new osteotomy methods and stability of plate fixation have provided scientific background for the development of improved surgical techniques that are more accurate, safer, and provide for quicker rehabilitation and bone healing. This article provides an overview of the basic principles behind the correction of femoral valgus deformity. Both the analysis and planning of femoral valgus deformity correction as well as the results of systematic clinical reviews are provided. The current recommended surgical technique of biplanar medial closing-wedge supracondylar osteotomy is explained, and the first clinical results are reported. Finally, the authors describe some of the future directions and needs for treatment optimization of patients with femoral valgus deformity.

Keywords
- closing-wedge osteotomy
- supracondylar osteotomy
- valgus leg correction

In 1996 in a specialty issue on "Early Gonarthrosis: Osteotomies of the Distal Femur and Proximal Tibia," the guest editor stated that after reviewing the literature, little new knowledge was available in this area.[1] Furthermore, he concluded that little advances had been made since the 1980s solving the technically demanding problems of corrective osteotomies (OTs) and that the emphasis subsequently had shifted to arthroplasty. Since then, however, insights have changed on development and progression of osteoarthritis (OA) in malaligned limbs, analysis and planning of correction of malaligned limbs has been better defined, and corrective OT techniques have dramatically improved.[2] In this evolution the first progress has been made in high tibial OTs for treatment of varus osteoarthritic knees. Only in the past decade major steps have been made in the treatment of valgus legs with lateral compartment ostearthritis. It is only logical that with newly developed surgical techniques until recently, no clinical studies have been reported. The interest in treatment of valgus deformed legs with femoral OTs as a joint preserving alternative to arthroplasty has rapidly increased though. In the past 5 years, no fewer than four systematic reviews have been published on varization supracondylar osteotomies (SCOs).[3–6] In these reviews, the literature available on results of varization SCOs has been analyzed from articles published between 1961 and 2015. Not surprisingly, some of the conclusions of these reviews were similar as often overlapping sets of articles had been analyzed. ►**Table 1** summarizes the most important findings and conclusions of these reviews. Because of lack of sufficient follow-up time for the systematic review criteria, no publications on the biplanar medial closing-wedge SCO technique were included.

Causes, Development, and Definition of Valgus Leg Deformities

A valgus leg alignment can be present congenitally or occur after lateral meniscectomy, growth plate disturbances, and/or post traumatically.[7] The valgus alignment itself is a risk factor for the development of lateral compartment OA and its progression.[8–10] Lateral compartment OA is most often located posterolaterally in the knee whereas medial

received
December 13, 2016
accepted after revision
March 9, 2017

DOI https://doi.org/10.1055/s-0037-1602137.
ISSN 1538-8506.

Table 1 Aims, findings, and conclusions of four systematic reviews on results of SCO

Authors	Aim	Findings	Conclusion
Saithna et al. (2012)	Define indications, functional outcome, survivorship, and complications	- Comparison of selected studies difficult due to lack of universal outcome measures. - No information on return to sports and impact activities. HSS score improvements ranging preoperative 46–56 to postoperative 72–88. - Survivorship endpoint arthroplasty ranges 64–82% at 10-y and 45% at 15-y follow-up. - Pooled results overall complication rate 5.8%.	Varization SCO is technically demanding and requires a significant period of rehabilitation for the patient. However, long-term survivorship and good function have been demonstrated, and it remains a potential option for valgus osteoarthritis in carefully selected patients.
Haviv et al. (2013)	Up-to-date overview of results varization OT for valgus OA	- All studies available level 4 small case series. - Most patients improve after correction. - High percentage of reoperations for nonunions, mechanical failure, plate irritation, and unresolved pain. - Long-term follow-up: overall failure rate 48.5% at 15 y and KM survival rate 89.9% (10 y), 78.9% (15 y) 21.5% at 20 year follow-up. - Prognostic good factors: milder OA, adequate correction, better fixation, early mobilization, no advanced osteoporosis.	The role of varus osteotomy remains poorly defined. The literature generally supports this procedure in active and cooperative patients to reduce pain and delay the need for knee replacement. Corrective varus osteotomy is a demanding procedure that follows important biomechanical principles and requires careful preoperative planning. New techniques hold promising results regarding shortening of rehabilitation time and low reoperation and complication rates.
Chahla et al. (2016)	Review on the survival, outcomes, and complications of SCO for genu valgum with lateral OA	- Good to excellent patient-reported outcomes in 9 closing-wedge and 5 opening-wedge SCO studies included - Survival decrease from 100% at 6.5 y to 21.5% at 20-y follow-up. - Low complication rate; symptomatic HW most prevalent postoperative complication.	Highly heterogeneous literature exists for both opening- and closing-wedge SCO for the treatment of isolated lateral compartment osteoarthritis with valgus malalignment. A mean survival rate of 80% at 10-y follow-up was reported, supporting that this procedure can be a viable treatment option to delay or reduce the need for joint arthroplasty.
Wylie et al. (2016)	To determine the radiologic c/h rate, patient-reported outcomes, reoperation rate, and complication rate after SCO To summarize the results of MCW and LOW SCO	- Mean radiographic correction to a near-neutral mechanical axis, with 3.2% nonunion and 3.8% delayed union rates. - A 9% complication rate and a 34% reoperation rate with 15% conversion to arthroplasty. - Similar results reported for MCW and LOW techniques, with higher conversion to arthroplasty in the MCW group that was confounded by longer mean follow-up.	SCOs for the valgus knee with lateral compartment disease provide improvements in patient-reported knee health-related quality of life at midterm follow-up but have high rates of reoperation. No evidence exists proving better results of either the LOW or MCW techniques.

Abbreviations: c/h, correction/healing; HSS, Hospital for Special Surgery; HW, hardware; KM, Kaplan-Meier; LOW, lateral open wedge; MCW, medial closing-wedge; OA, osteoarthritis; OT, osteotomy; SCO, supracondylar osteotomy.

compartment OA is located anteromedially.[11,12] Anatomically the lateral tibia plateau is convex, instead of concave medially; congruency of the lateral compartment is to a much larger extent maintained by the shape of the lateral meniscus, and loss of the integrity of the lateral meniscus decreases this congruency.[13] The biomechanics of a valgus malalignment, therefore, might be entirely different compared with a varus malalignment.[14] Various authors have looked at the differences between lateral and medial OA. Recent research on cartilage forces and associations between variations in anatomy around the hip and leg alignment might better explain why cartilage in lateral OA deteriorates more rapidly in specific patients.[11,14–24]

Deformity analysis will help find the patient in which a valgus leg deformity is caused by a femoral deformity. Paley[25] describes a comprehensive system of measurements of bones and joint line angles, and defines that a femoral valgus deformity is present when the so-called mLDFA (mechanical lateral distal femoral angle) is < 88 degrees. In knee joints with distal femoral deformities and valgus joint line obliquity, a femoral correction not only corrects the leg alignment but also normalizes the knee joint line obliquity and the mLDFA. In many patients, however, the valgus malalignment may be found to be caused by a tibial or a combined tibial and femoral deformity.[26] The principles of deformity correction as formulated by Paley[25] dictate that in these cases either a tibial correction or a double-level OT should be performed with a resultant normal knee joint line orientation. Planning of correction using present and desired weightbearing lines provides for the angle of correction as well as the length of the wedge base on the cortex (►**Fig. 1**).

Besides patients with OA of the lateral compartment in combination with valgus deformity of the femur, indications for corrections consist of patients with posttraumatic and congenital valgus deformities of the femur.[27] In addition, an SCO may be considered in valgus malaligned legs (1) with ligamentous deficiency that has failed primary repair or reconstruction requiring revision, (2) with focal lateral compartment cartilage defect requiring treatment, (3) with lateral meniscus deficiency, and (4) with recurrent patella instability.[6] Contraindications for an SCO consist of patients with OA of the medial compartment ($\geq$ grade 3 on Outerbridge scale) and patients who have a total loss of the medial meniscus after previous surgery. Furthermore, acute or chronic infections around the knee as well as rheumatoid arthritis are reasons to exclude patients. Finally, patients with knee extension or flexion deficit > 20 degrees and poor soft tissue conditions on the site of surgery as well as heavy smokers should preferably not be indicated for an SCO.

Basic Principles behind Osteotomies for Valgus Correction

While a varization SCO is biomechanically efficient in the extended knee, it should be noted that in flexion the OT has no effect.[28] In 90 degrees of flexion, the contact point of the loaded posterior condyles on the tibia remains unchanged by the SCO. Patients, therefore, should be warned that while excellent symptoms relief may be expected in extension and during gait, symptoms are likely to persist during activities that load the knee in high flexion.

There is no consensus in varus SCO on the optimal amount of correction. A correction of the anatomical femorotibial axis to 6 to 10 degrees[29–34] or mechanical femorotibial axis between 0 and 3 degrees varus has all been recommended.[14,35–38] Miniaci et al[39] reported that poor results were associated with longer time to follow-up and failure to correct the tibiofemoral angle to 0 degrees. Similarly Mathews et al[40] reported that good results were associated with adequate correction of the valgus deformity, to < 2 degrees from 0. McDermott et al[31] and Cameron et al,[35] on the other hand, found no correlation between alignment and outcome. All these authors aimed for correction of the anatomical axis of the femur to 0 degree. Teitge[14] noted that with correct alignment deterioration was slow and that those with a less than good result were poor from the start; in those the indication to perform an OT might not have been correct. The current authors correct the mechanical axis to a line passing the knee joint just medial to the deepest point of the trochlea. In severe lateral OA, in the presence of a normal medial compartment, a line slightly medial to that, that is, just medial of the medial eminence of the tibial plateau, is used.

The medial closing-wedge technique, with saw cuts either parallel to the joint line or oblique downsloping from the medial cortex to the lateral cortex hinge point, fixed with an angled blade plate, has had the most widespread use.[14,29–33,39,41] Stähelin et al[42] showed by measurement of bone diameters at the level of the bone cuts that, using oblique directed bone cuts of equal length forming an isosceles triangle, the bone diameter at the level of the OT cuts is equal (►**Fig. 1**). After closure of the OT, the medial cortex can be compressed without change of correction, contrary to bone cuts aligned parallel to the joint line, resulting in unequal bone diameters causing impaction and overcorrection after compression of the OT. In recent years the conventional single plane OT technique has been replaced by the biplanar technique. An important limitation of the single plane medial closing-wedge technique is the position of the OT relative to the trochlea and the soft tissue gliding surface on the anterior side of the femur.[37,43] While in the standard single plane technique the patellofemoral (PF) joint is avoided by proximal positioning of the saw cuts, the OT disrupts the soft tissue gliding mechanism causing a hematoma with subsequent pain and swelling that slows rehabilitation. A modification was, therefore, developed: the biplane medial closing-wedge technique.[37] In this technique the two saw cuts for the closing wedge are made only in the posterior three-quarters of the femur after which an ascending saw cut is performed on the anterior surface of the femur, completing the OT. By avoiding the trochlea, this technique enables a more distal positioning of the lateral hinge point in better healing metaphyseal bone. As the soft tissue gliding mechanism is not disrupted, rehabilitation is faster.[44] Furthermore, the ascending saw cut increases the cortical contact area, which enhances stability and bone healing potential.[37,45]

Fig. 1 Planning of a medial closing-wedge supracondylar osteotomy according to Miniaci et al.[39] (**A**) The present mechanical axis is drawn from A, the center of the femoral head, to B, the center of the ankle joint. Line B–C is of equal length as line A–B and passes the knee just medial of the medial eminence (arrow) representing the desired postoperative mechanical axis. (**B**) The hinge point of the osteotomy (D) is marked just proximal from the upper border of the lateral condyle and 0.5–1 cm within the lateral cortex. The angle of correction (α) is defined by line A–D between the present femoral head center and the hinge point and line C–D connecting the new femoral head center position and the hinge point. (**C**) Correction angle α is projected at the distal femur using two oblique down sloping lines of equal length converging at the hinge point. The distance measured between those two lines at the level of the medial cortex (arrows) represents the osteotomy wedge base length to be removed during surgery. (Reprinted with permission from Brinkman JM. Fixation stability and new surgical concepts of osteotomies around the knee, [PhD. dissertation]. Utrecht, The Netherlands: Utrecht University Medical Center; 2013).[57]

The general principles of bone healing apply to closing-wedge OTs, which can be considered optimally controlled fractures treated according to standard protocols for fracture treatment, with radiographs taken at regular intervals to monitor bone healing. Bone healing in closing-wedge OTs, however, may be faster than in fractures if initial stability is optimal because the hinge point remained intact. Bone healing in the distal femur then is normally complete after 6 to 8 weeks. Methods to prevent hinge point fracture are careful clearance of uneven saw cut surfaces and bone remnants after wedge removal, weakening of the lateral cortex before closure by chisels or small bur holes, and a slow-paced wedge closure. Initial stability can be furthermore optimized by using oblique saw cuts and compressing the OT using either a compression device or a compression screw technique. Similar to fractures, bone healing in OTs is slowed by smoking and instability, insufficient implant fixation strength, and hinge fracture. Bone geometry and wedge volume after SCO have been found superior in biplane medial closing-wedge SCO as compared with lateral open and single plane medial closing techniques; in the biplane technique, a smaller wedge volume and a larger bone surface contact area are created, which improves bone healing and stability.[45]

More recently angle stable implants, based on the LCP concept, specifically designed for the fixation of SCO have become available.[36–38,46] By changing the fixation technique to a plate fixator, the difficulties encountered using an angled blade plate, which caused surgeons to refrain from SCO altogether, are avoided. These difficulties include inaccurate positioning of the seating chisel and loss of stability after repositioning. This also avoids secondary displacement due to fracture of the hinge after removing the seating chisel and inserting the angled blade plate.

Baseline data on the initial stability of the various SCO techniques have become available.[43,47,48] In three biomechanical studies, partial and full weightbearing conditions after SCO corrections in replicate bones were studied. In the first study the biomechanical properties of five different SCO techniques have been evaluated.[47] The angled-blade plate and the TomoFix Medial Distal Femur plate (Synthes GmbH, Solothurn, Switzerland), using an oblique OT direction, provided the largest amount of initial stability. The parallel OT compared with the oblique OT and the lateral open technique, whether fixated with angle stable or spacer plates, were less stable. In a second study the aforementioned biplane OT was found to be more stable than the standard single plane SCO.[43] Subsequently, in a third study previous results on biplane SCO stability were reconfirmed using an improved, more anatomically shaped version of the angle stable (TomoFix) plate.[48]

New Surgical Technique and First Clinical Results

The senior author's preferred surgical technique is a biplane medial closing-wedge OT fixated with an LCP concept–based plate fixator called TomoFix medial distal femur plate (TomoFix MDF, Synthes GmbH, Solothurn, Switzerland) (►**Fig. 2**).[37] Arthroscopy, which is considered as indispensable by some, can be performed prior to the OT to assess the cartilage and

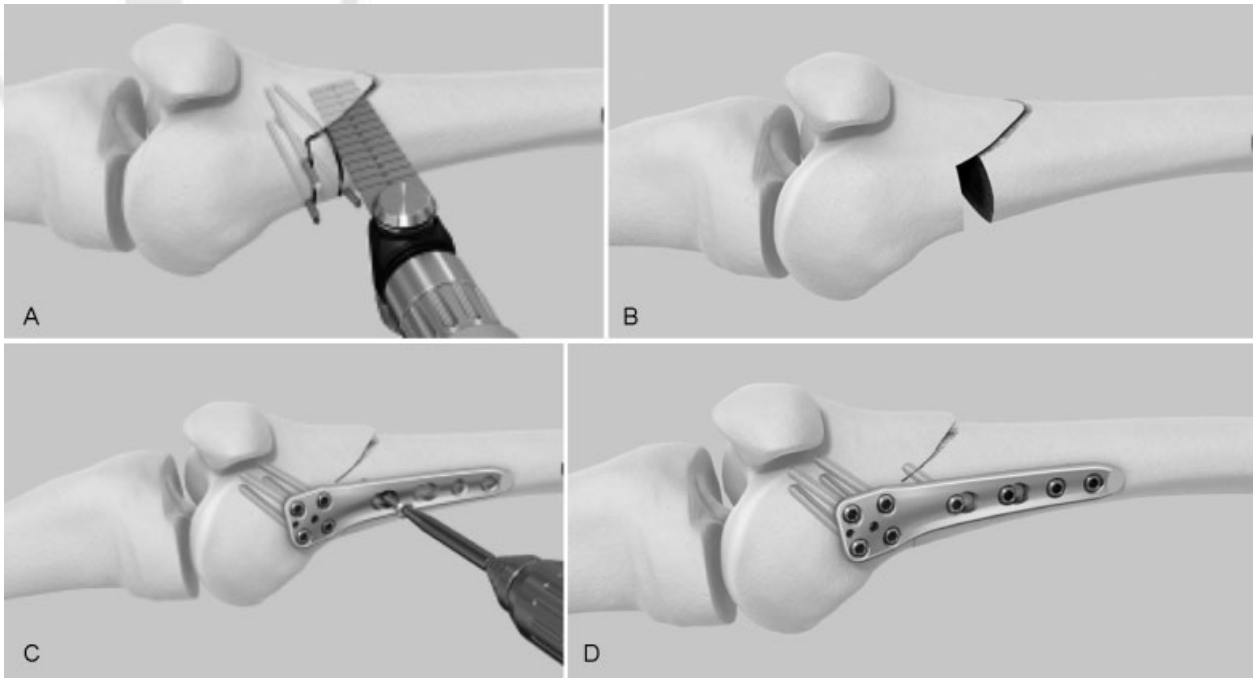

Fig. 2 Stepwise schematic representation of the surgical technique for a biplane closing-wedge supracondylar femur osteotomy fixated by an internal fixator plate. (**A**) After the transverse cuts have been made, the ascending cut of the biplane osteotomy is performed parallel to the posterior cortex. (**B**) The wedge is removed and the osteotomy closed. (**C**) After distal plate fixation, a lag screw is inserted to compress the osteotomy. (**D**) The lag screw is replaced with a locking screw after the other proximal holes have been filled. (Reprinted and modified with permission from Brinkman JM. Fixation stability and new surgical concepts of osteotomies around the knee, [PhD. dissertation]. Utrecht, The Netherlands: Utrecht University Medical Center; 2013).[57]

menisci; if needed, additional procedures, including microfracturing, can be performed.[49] The whole leg should be draped free and a sterile tourniquet can be applied. The starting position of the knee is in full extension. An image intensifier fluoroscope is mandatory, with visualization possible in two directions. The medial side of the distal femur can be exposed by either a median or anteromedial incision and a standard subvastus approach, in which the muscle needs to be stripped of the septum severing vessels and nerves at a length enabling plate fixation. A blunt Hohmann retractor is positioned dorsomedially at the level of the OT to protect the neurovascular structures. The height and direction of the OT cuts are marked with K-wires using fluoroscopy. The first K-wire for the distal saw cut is inserted at the medial cortex aimed at an approximately 20 degrees downsloped direction ending a few millimeters above the upper portion of the lateral femur condyle and 5 to 10 mm medial to the lateral cortex (►**Fig. 1**). The second K-wire is inserted proximally at the preplanned wedge base distance on the medial cortex; the ends of both K-wires meet at the hereby created hinge point of the OT. Ideally, the K-wires form an isosceles triangle which can be checked by measuring the length of the K-wires outside the bone. Two additional K-wires can be positioned more posterior at the same height to guide the saw blade. Alternatively, a special saw guide can be used to precisely determine wedge size and direction. Two saw cuts are made parallel to and within the K-wires, but only in the posterior three-quarters of the femur. A third ascending saw cut is then performed to complete the OT, parallel to the posterior cortex, usually at an angle of 90 to 95 degrees to the other saw cuts. After wedge removal, the OT is closed by applying gentle pressure; this can take a couple of minutes to allow for plastic deformation of the bone. All bone should be removed from the gap before closure to prevent incomplete closure and lateral cortex fracture. After closure, the alignment is checked using a rigid bar over the center of the femoral head and center of the ankle joint; the new mechanical axis should run as preoperatively planned. If needed, adjustments can still be made to the OT at this time. The plate is slid proximally under the vastus medialis (VM) muscle until it is aligned with the femur shaft and then positioned anteromedially on the distal femur. After distal fixation, the OT is compressed manually. For additional compression, an eccentrically placed screw in the dynamic part of the combination hole directly proximal the OT is used. The plate is secured proximally using three unicortical screws, and one bicortical screw just proximal from the OT replacing the compression screw. The wound is closed after placement of a low vacuum suction drain under the VM.

Postoperative cryotherapy and intermittent venous compression are recommended to reduce swelling. Starting on the first postoperative day, partial weightbearing (15–20 kg) is allowed for the first 6 weeks. It is increased thereafter depending on pain and signs of bone healing on follow-up radiographs. For SCO in clinical studies reporting on the single plane technique with the TomoFix implant, no bone healing problems have been reported with a standard rehabilitation protocol consisting of 6 to 8 weeks of partial weightbearing.[37,38,44] However, after introduction of the biplane technique, a faster recovery of knee function was observed by the current authors as compared with the single plane patient groups. Patients themselves increased the amount of weightbearing within the first 6 weeks after the OT as they experienced sufficient stability to allow full weightbearing. Although Brinkman et al[43] demonstrated that the biplane OT is much more stable than single plane OT under axial loads, they found torsional stability to be slightly decreased. Therefore, postoperatively physical activities, which produce high torsion loads on the femur, are probably best avoided until bone healing has been observed.

Clinical results seem to correlate with the biomechanical observations concerning construct fixation strength and bone healing of the biplane OT technique. Van Heerwaarden et al[38] reported no loss of correction related to the implant and no failures of fixation material in 59 single plane OTs fixated with the TomoFix plate. Freiling et al[37] reported on 60 medial closing-wedge OTs half of which were biplane and found three nonunions overall, none of which were related to implant failure. Lobenhoffer et al[50] analyzed bone healing clinically in a consecutive series of 107 biplanar SCOs and found uneventful progression to full bone healing within 4 to 6 weeks after the surgery in 103 patients. In four patients a delayed union was treated with spongiosa plasty and reinforcement of the lateral hinge point using an additional small-fragment plate.

Patient evaluations on the medial closing-wedge biplane SCO can be found in two large studies.[37,51] Freiling et al (2010) described the results of their first series of 30 biplanar closing-wedge varization OTs together with the results of 30 single plane closing-wedge OTs. At a mean follow-up of 21 months, the preoperative Tegnerscore of 2.8 (1–4) had improved to 5.6 (2–9). The mean visual analogue scale (VAS) scores decreased from 6.8 (9–2) preoperatively to 3.1 (0–8) at follow-up. The patients were also evaluated using the IKDC (International Knee Documentation Committee) classification (18 patients grade A, 27 grade B, 9 grade C, and 6 grade D). No comparison has been made between the single plane and biplane technique, so no specific clinical results can be attributed to the biplanar technique. In the study by Elson et al (2015), 80 biplanar medial closing-wedge varization SCOs were part of a group of 109 SCOs reported on in a multicenter case series. At a mean follow-up of 28 months in the combined group, all outcome measures improved: mean KOOS 38.8 to 61.8, mean OKS 21.4 to 33.3, VAS pain 54.8 to 24.7. Postoperative VAS satisfaction was 8.0. Complications observed were: 3 delayed unions, 3 deep infection, 2 thromboembolic complications (1 deep vein and 1 fatal pulmonary embolus), 2 SCOs were converted to arthroplasty and 2 were revised for under correction. Studies on the results of biplanar medial closing-wedge SCOs with longer follow-up times will be published in the next years.

The Future: Gait, Sports, and MIS

Optimization of rehabilitation protocols with normalization of gait pattern and ability to return to sports activities will

further improve functional outcomes. Furthermore, a mini-invasive surgical approach causing less soft tissue damage will probably improve the results of biplanar medial closing-wedge SCOs.

Recently a prospective study has been published on the changes in kinetics and kinematics of gait and clinical outcomes after a varus OT in patients with OA of the knee and a valgus leg alignment.[52] In that study preoperative and postoperative gait parameters were analyzed and compared with healthy subjects in three groups of varization OTs: medial closing-wedge tibial OTs, medial closing-wedge SCOs and double OTs. A differentiated approach was used based on retention of normal knee joint orientation after correction resulting in the three different patient groups with isolated tibial, isolated femoral or combined tibial and femoral valgus bone deformities, respectively. Postoperatively, the patients showed kinetics and kinematics of gait similar as that of a healthy control group. A significant increase in the knee adduction moment during stance phase was found for patients after all types of correction OTs, which was related to the degree of correction. The HKA angle toward zero degrees caused a medial shift in the dynamic knee loading.

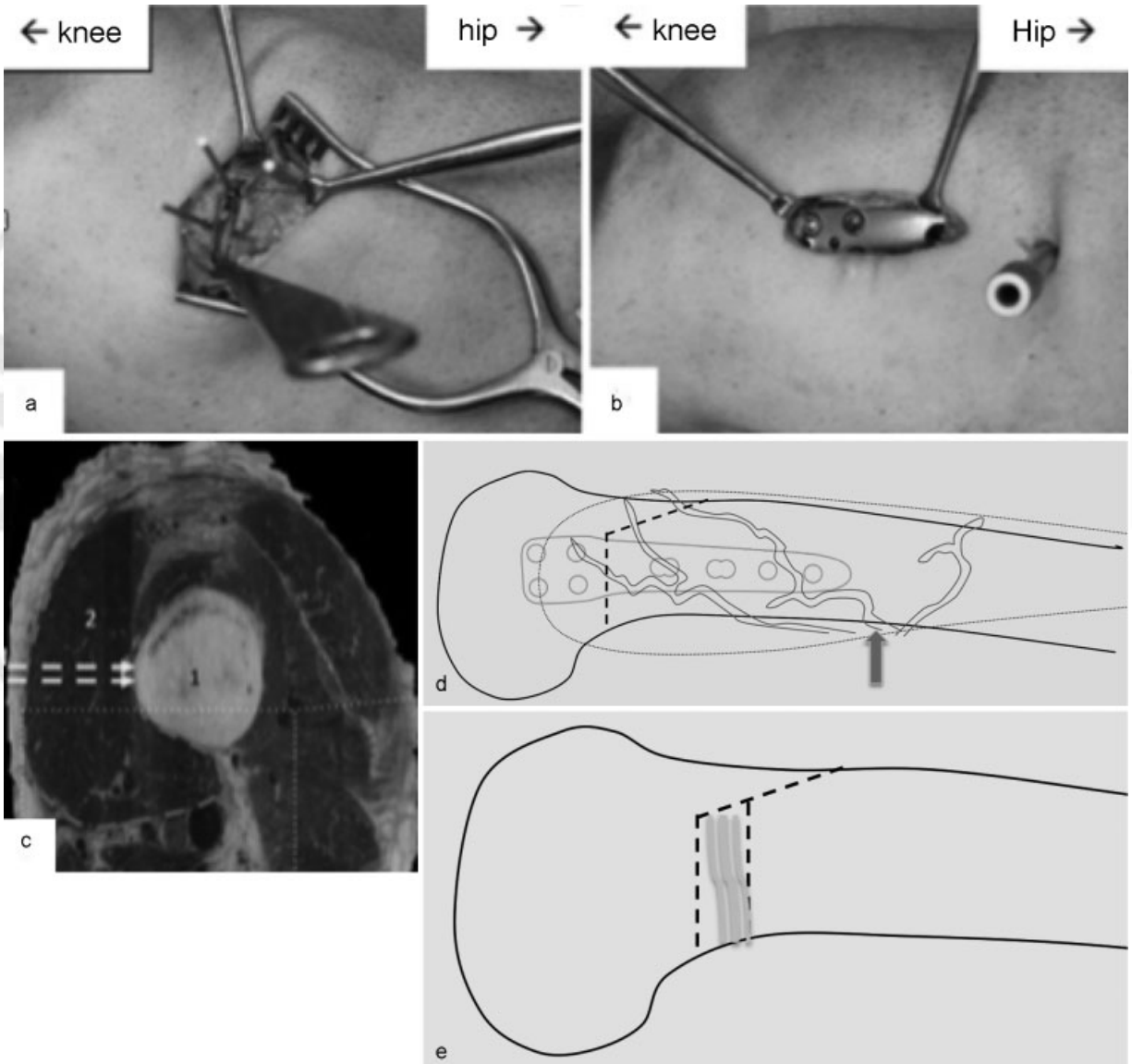

Fig. 3 Less invasive approach for medial closing-wedge distal femoral osteotomy. (**A**) Medial view of less invasive approach in a cadaveric right leg. Distal part of the vastus medialis muscle is retracted ventrolateral with small soft tissue retractors. K-wires inserted to guide saw cuts of biplanar osteotomy cuts, and small Hohman retractor protects posterior soft tissues. (**B**) Plate fixation: distal screws and first screw proximal of osteotomy inserted, drill sleeve positioned in most proximal plate hole through stab incision. (**C**) Left femur cadaver specimen cryomicrotome coronal section 12 cm above the knee joint line. The traditional subvastus approach (gray striped line) and the percutaneous approach (arrowhead white lines) are projected (1 femur; 2 vastus medialis muscle). (**D**) Schematic representation of the descending genicular artery (arrow) and its branches as found within the vastus medialis muscle projected on the femur. Femoral artery, adductor magnus tendon, biplane osteotomy, and plate are also projected on the femur. (**E**) Schematic representation of the periosteal vascularization (upper transverse artery and venae comitantes) and osteotomy cuts of biplanar closing-wedge osteotomy projected on the femur. (Figs. A-D Reprinted and modified, with permission, from Brinkman JM. Fixation stability and new surgical concepts of osteotomies around the knee, [PhD. dissertation]. Utrecht, The Netherlands: Utrecht University Medical Center; 2013).[57]

Furthermore, a significant improvement in all clinical outcomes was found as well as no differences between the different OT groups. This was the first gait analysis study we know of that with specific notice to location specific valgus deformity correction analyzed gait in a small group of medial closing-wedge SCO patients. Larger groups of patients should be analyzed in the future to answer remaining questions, for example, as to what the optimal alignment is to aim for in varization OTs.

Return to sports activities after varization SCOs has specifically been reported in only two studies.[53,54] In one study at mean 4 years follow-up after OT, almost 60% of 28 patients returned to preoperative physical activity levels and some patients increased the number and type of exercises.[53] In the other study, a consecutive series of 13 athletic patients was prospectively reviewed at 2 years follow-up after distal femoral varization OT.[54] All patients were able to return to their sports activity of at least 4 days a week. Six patients were treated with medial closing-wedge OTs fixed with the TomoFix plate; the others with lateral open-wedge OTs and concomitant chondral, meniscal, and ligamentous pathology had also been addressed. Future studies focusing on sports participation and return to work after SCOs will make a comparison with patients conservatively treated or with (hemi-)arthroplasties possible. This will further help physicians and patients on deciding which treatment to choose for the symptomatic femoral valgus deformity.

In the minimally invasive approach of the biplanar medial closing-wedge femoral OT, the distal screws and the OT-compression screw are inserted through a small medial incision made at the level of the OT (►**Fig. 3**).[55] Instead of stripping the VM muscle off its septum as in the standard subvastus technique, the natural interval between the distal femur and VM is used to lift the muscle ventrally. The remaining proximal screws for plate fixation are inserted through a separate transmuscular stab incision positioned at the most proximal plate hole avoiding damage to major neurovascular structures. This technique was found to be feasible and safe. Damage to the VM and its neurovascular structures is minimized as compared with the traditional subvastus approach.

Particularly helpful in minimally invasive surgery are landmarks that can be visualized on fluoroscopy (e.g., the upper border of the lateral femoral condyle) as well as landmarks that can be seen through the keyhole incision used for the OT. In standard exposures it was observed that in the medial cortical area where the OT cuts were positioned ideally, typically three periosteal vessels were found (►**Fig. 3**). An anatomical study was performed to investigate whether these periosteal vessels location could be used as an intraoperative landmark in mini-invasive SCOs.[56] In cadaver specimens, the vascular supply of the medial and lateral aspects of the femoral condyle was found to be highly constant. It was concluded that the upper transverse artery with its two venae comitantes can serve as a landmark in determining the height of the OT cuts in medial SCOs. Transection of these landmark periosteal vessels during the OT will not result in vascular insufficiency because of a collateral supply. Effectively, in the mini-invasive approach, the surgeon now can rely on the position of these periosteal vessels as the insertion place of K-wires for an optimized location of the OT cuts.

Instruments to assist the surgeon in mini-invasive OT surgery need to be developed to further optimize this surgical technique.

Conclusion

Correction of valgus femoral deformity is a viable treatment option for a well-defined patient group suffering from valgus malalignment and lateral compartment OA. The new biplane medial closing-wedge OT technique fixed with a locking compression plate has evolved from the previously used single plane technique and has extensively been investigated. This technique is very stable, and bone healing potential is optimal, which allows for shortening of rehabilitation time without loss of correction. More patient studies with longer follow-up are necessary to enable a comparison with alternative surgical techniques and historical cohort studies.

References

1 Teitge RA. . Introduction. Semin Arthroplasty 1996;7:113en
2 Seil R, van Heerwaarden R, Lobenhoffer P, Kohn D. The rapid evolution of knee osteotomies. Knee Surg Sports Traumatol Arthrosc 2013;21(01):1–2
3 Saithna A, Kundra R, Modi CS, Getgood A, Spalding T. Distal femoral varus osteotomy for lateral compartment osteoarthritis in the valgus knee. A systematic review of the literature. Open Orthop J 2012;6:313–319
4 Haviv B, Bronak S, Thein R, Thein R. The results of corrective osteotomy for valgus arthritic knees. Knee Surg Sports Traumatol Arthrosc 2013;21(01):49–56
5 Chahla J, Mitchell JJ, Liechti DJ, et al. Opening- and closing-wedge distal femoral osteotomy: a systematic review of outcomes for isolated lateral compartment osteoarthritis. Orthop J Sports Med 2016;4(06):2325967116649901
6 Wylie JD, Jones DL, Hartley MK, et al. Distal femoral osteotomy for the valgus knee: medial closing wedge versus lateral opening wedge: a systematic review. Arthroscopy 2016;32(10): 2141–2147
7 Gugenheim JJ Jr, Brinker MR. Bone realignment with use of temporary external fixation for distal femoral valgus and varus deformities. J Bone Joint Surg Am 2003;85-A(07):1229–1237
8 Sharma L, Song J, Felson DT, Cahue S, Shamiyeh E, Dunlop DD. The role of knee alignment in disease progression and functional decline in knee osteoarthritis. JAMA 2001;286(02):188–195
9 Sharma L, Song J, Dunlop D, et al. Varus and valgus alignment and incident and progressive knee osteoarthritis. Ann Rheum Dis 2010;69(11):1940–1945
10 Felson DT, Niu J, Gross KD, et al. Valgus malalignment is a risk factor for lateral knee osteoarthritis incidence and progression: findings from the Multicenter Osteoarthritis Study and the Osteoarthritis Initiative. Arthritis Rheum 2013;65(02):355–362
11 Weidow J, Pak J, Kärrholm J. Different patterns of cartilage wear in medial and lateral gonarthrosis. Acta Orthop Scand 2002;73(03): 326–329
12 Gulati A, Chau R, Beard DJ, Price AJ, Gill HS, Murray DW. Localization of the full-thickness cartilage lesions in medial and lateral unicompartmental knee osteoarthritis. J Orthop Res 2009;27(10): 1339–1346

13 Puddu G, Cipolla M, Cerullo G, Franco V, Giannì E. Osteotomies: the surgical treatment of the valgus knee. Sports Med Arthrosc Rev 2007;15(01):15–22
14 Teitge RA. Supracondylar osteotomy for lateral compartment ostearthritis. Semin Arthroplasty 1996;7:192–211
15 Lindgren U, Seireg A. The influence of mediolateral deformity, tibial torsion, and foot position on femorotibial load. Prediction of a musculoskeletal computer model. Arch Orthop Trauma Surg 1989;108(01):22–26
16 Wang JW, Kuo KN, Andriacchi TP, Galante JO. The influence of walking mechanics and time on the results of proximal tibial osteotomy. J Bone Joint Surg Am 1990;72(06):905–909
17 Harrington IJ. Static and dynamic loading patterns in knee joints with deformities. J Bone Joint Surg Am 1983;65(02):247–259
18 Johal P, Williams A, Wragg P, Hunt D, Gedroyc W. Tibio-femoral movement in the living knee. A study of weight bearing and non-weight bearing knee kinematics using 'interventional' MRI. J Biomech 2005;38(02):269–276
19 Allen PR, Denham RA, Swan AV. Late degenerative changes after meniscectomy. Factors affecting the knee after operation. J Bone Joint Surg Br 1984;66(05):666–671
20 Peña E, Calvo B, Martinez MA, Palanca D, Doblaré M. Why lateral meniscectomy is more dangerous than medial meniscectomy. A finite element study. J Orthop Res 2006;24(05):1001–1010
21 Yang N, Nayeb-Hashemi H, Canavan PK. The combined effect of frontal plane tibiofemoral knee angle and meniscectomy on the cartilage contact stresses and strains. Ann Biomed Eng 2009;37 (11):2360–2372
22 Weidow J, Tranberg R, Saari T, Kärrholm J. Hip and knee joint rotations differ between patients with medial and lateral knee osteoarthritis: gait analysis of 30 patients and 15 controls. J Orthop Res 2006;24(09):1890–1899
23 Weidow J, Mars I, Kärrholm J. Medial and lateral osteoarthritis of the knee is related to variations of hip and pelvic anatomy. Osteoarthritis Cartilage 2005;13(06):471–477
24 Andriacchi TP. Dynamics of knee malalignment. Orthop Clin North Am 1994;25(03):395–403
25 Paley D. Principles of Deformity Correction. New York, NY: Springer-Verlag; 2002:1–154
26 Hofmann S, van Heerwaarden RJ. Algemeine Patientenauswahl und Indikationen zu Doppelosteotomien. Orthop Prax 2008; 43:142–146
27 Brinkman JM, Freiling D, Lobenhoffer P, Staubli AE, van Heerwaarden RJ. [Supracondylar femur osteotomies around the knee. Patient selection, planning, operative techniques, stability of fixation, and bone healing] [German]. Orthopade 2014;43(11):988–999
28 Chambat P, Ait Si Selmi T, Dejour D. Varus tibial osteotomy. Osteotomies about the athletic knee. Oper Tech Sports Med 2000;8:44–47
29 Wang JW, Hsu CC. Distal femoral varus osteotomy for osteoarthritis of the knee. J Bone Joint Surg Am 2005;87(01):127–133
30 Healy WL, Anglen JO, Wasilewski SA, Krackow KA. Distal femoral varus osteotomy. J Bone Joint Surg Am 1988;70(01):102–109
31 McDermott AG, Finklestein JA, Farine I, Boynton EL, MacIntosh DL, Gross A. Distal femoral varus osteotomy for valgus deformity of the knee. J Bone Joint Surg Am 1988;70(01):110–116
32 Finkelstein JA, Gross AE, Davis A. Varus osteotomy of the distal part of the femur. A survivorship analysis. J Bone Joint Surg Am 1996;78(09):1348–1352
33 Learmonth ID. A simple technique for varus supracondylar osteotomy in genu valgum. J Bone Joint Surg Br 1990;72(02): 235–237
34 Terry GC, Cimino PM. Distal femoral osteotomy for valgus deformity of the knee. Orthopedics 1992;15(11):1283–1289, discussion 1289–1290
35 Cameron HU, Botsford DJ, Park YS. Prognostic factors in the outcome of supracondylar femoral osteotomy for lateral compartment osteoarthritis of the knee. Can J Surg 1997;40(02):114–118
36 Freiling D, Lobenhoffer P, Staubli A, van Heerwaarden RJ. Medial closed-wedge varus osteotomy of the distal femur. Arthroskopie 2008;21:6–14
37 Freiling D, van Heerwaarden R, Staubli A, Lobenhoffer P. [The medial closed-wedge osteotomy of the distal femur for the treatment of unicompartmental lateral osteoarthritis of the knee] [in German]. Oper Orthop Traumatol 2010;22(03): 317–334
38 van Heerwaarden RJ, Wymenga AB, Freiling D, Lobenhoffer P. Distal medial closed wedge varus femur osteotomy stabilized with the Tomofix plate fixator. Oper Tech Orthop 2007; 17:12–21
39 Miniaci A, Grossmann SP, Jakob RP. Supracondylar femoral varus osteotomy in the treatment of valgus knee deformity. Am J Knee Surg 1990;3:65–73
40 Mathews J, Cobb AG, Richardson S, Bentley G. Distal femoral osteotomy for lateral compartment osteoarthritis of the knee. Orthopedics 1998;21(04):437–440
41 Marti RK, Schroder J, Witteveen A. The closed wedge varus supracondylar osteotomy. Oper Tech Sports Med 2000; 8:48–55
42 Stähelin T, Hardegger F, Ward JC. Supracondylar osteotomy of the femur with use of compression. Osteosynthesis with a malleable implant. J Bone Joint Surg Am 2000;82(05):712–722
43 Brinkman JM, Hurschler C, Staubli AE, van Heerwaarden RJ. Axial and torsional stability of an improved single-plane and a new biplane osteotomy technique for supracondylar femur osteotomies. Knee Surg Sports Traumatol Arthrosc 2011;19(07):1090–1098
44 Takeuchi R, Martijn C, van Heerwaarden R, Seil R. Rehabilitation after osteotomies around the knee. Lobenhoffer P, van Heerwaarden R, Agneskirchner JD. Kniegelenknahe Osteotomien. Indikation, Planung, Operations technik mit Plattenfixateuren. Stuttgart, Germany; New York, NY: Thieme; 2014:150–158
45 van Heerwaarden R, Najfeld M, Brinkman M, Seil R, Madry H Pape D. Wedge volume and osteotomy surface depend on surgical technique for distal femoral osteotomy. Knee Surg Sports Traumatol Arthrosc 2013;21(01):206–212
46 van Heerwaarden RJ, Hurschler C, Brinkman JM. Superior axial stability of a new biplane osteotomy technique for supracondylar femur osteotomies fixed with an angular stable plate. Knee Surg Sports Traumatol Arthrosc 2010;18(Suppl 1(SCP10–1068): S101
47 Brinkman JM, Hurschler C, Agneskirchner JD, Freiling D, van Heerwaarden RJ. Axial and torsional stability of supracondylar femur osteotomies: biomechanical comparison of the stability of five different plate and osteotomy configurations. Knee Surg Sports Traumatol Arthrosc 2011;19(04):579–587
48 Brinkman JM, Hurschler C, Agneskirchner J, Lobenhoffer P Castelein RM, van Heerwaarden RJ. Biomechanical testing of distal femur osteotomy plate fixation techniques: the role of simulated physiological loading. J Exp Orthop 2014;1(01):1
49 Müller M, Strecker W. Arthroscopy prior to osteotomy around the knee? Arch Orthop Trauma Surg 2008;128(11):1217–1221
50 Freiling D, van Heerwaarden R, Staubli A, Lobenhoffer P. The medial closed-wedge osteotomy of the distal femur for the treatment of unicompartmental lateral osteoarthritis of the knee. Oper Orthop Traumatol 2010;22(03):317–334
51 Elson DW, Mahoney M, Yasen SK. Distal Femoral Osteotomy—A Large Multicentre Case Series. Paper presented at: 10th Biennial ISAKOS Congress. Lyon, France; June 72015
52 van Egmond N, Stolwijk N, van Heerwaarden R, van Kampen A, Keijsers NLW. Gait analysis before and after corrective osteotomy in patients with knee osteoarthritis and a valgus deformity. Knee Surg Sports Traumatol Arthrosc 2016[Epub ahead of print]
53 de Carvalho LH Jr, Temponi EF, Soares LF, Gonçalves MB, Costa LP, ve Carvalho LH. Physical activity after distal femur osteotomy for the treatment of lateral compartment knee osteoarthritis. Knee Surg Sports Traumatol Arthrosc 2014;22(07):1607–1611

54 Voleti PB, Degen R, Tetreault D, Krych AJ, Williams RJ. Successful return to sport following distal femoral varus osteotomy. Orthop J Sports Med 2016;4(7 Suppl 4). doi: 10.117/2325gb7116500132
55 Visser J, Brinkman JM, Bleys RLAW, Castelein RM, van Heerwaarden RJ. The safety and feasibility of a less invasive distal femur closing wedge osteotomy technique: a cadaveric dissection study of the medial aspect of the distal femur. Knee Surg Sports Traumatol Arthrosc 2013;21(01):220–227
56 van der Woude JA, van Heerwaarden RJ, Bleys RL. Periosteal vascularization of the distal femur in relation to distal femoral osteotomies: a cadaveric study. J Exp Orthop 2016; 3(01):6
57 Brinkman JM. Fixation stability and new surgical concepts of osteotomies around the knee [Ph.D. dissertation]. Utrecht, The Netherlands: Utrecht University Medical Center; 2013